

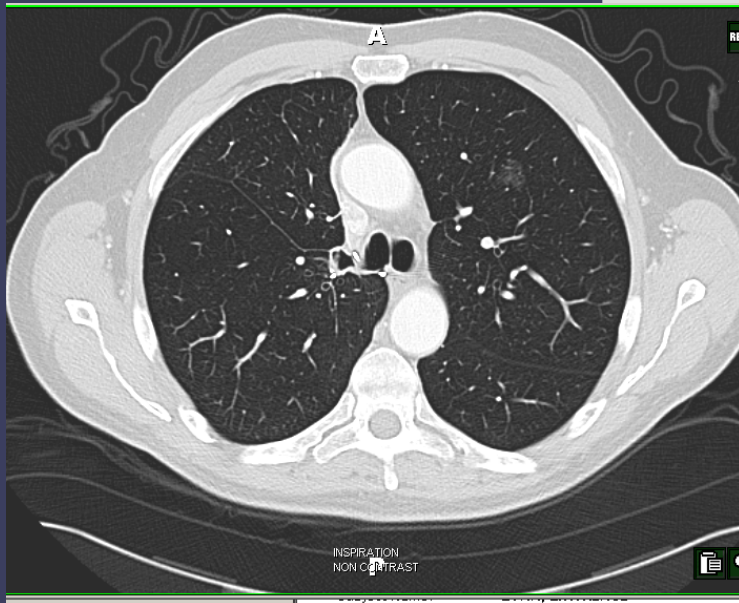
Approach to Aspergillosis

Kieren A. Marr MD

Director, Transplant and Oncology ID

Johns Hopkins University School of Medicine

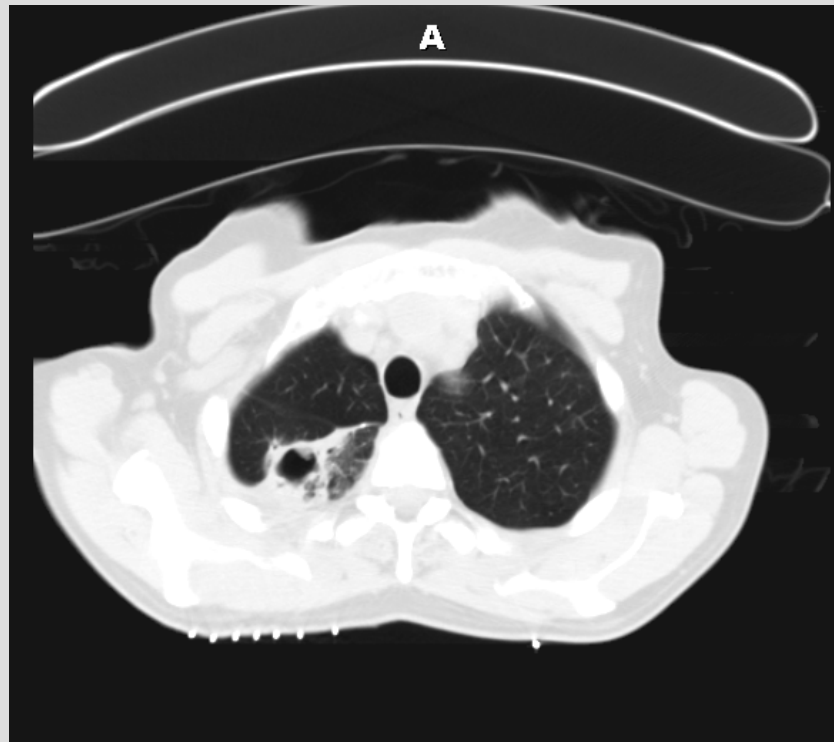
Case Presentation: HPI



- Patient from VA has a history of stage IA bronchoalveolar carcinoma of his right upper lobe, which was resected in 03/04.
- At the end of 2007, it was noted that he had a left upper lobe ground-glass nodular infiltrate.
- PET scan showed no evidence of increased metabolic activity
- Lesion had been followed with serial imaging.
- A CT in 05/08 showing there was stability in the size of the left upper lobe ground- glass nodule at 1.7 cm.

Case Presentation: HPI

- In 09/08 when he developed:
 - fever, chills, malaise, headaches, and muscle aches
- CT showed a cavitary lesion in the right upper lobe (same location of initial lesion)



Case Presentation: HPI

- A PPD was placed non-reactive
- Bronchoscopy with BAL:
 - All cultures from that specimen are no growth to date
- Started on Augmentin, which was taken from 09/19 to 10/03.

Case

- His cavitory lesion did not resolve and he subsequently underwent a CT-guided biopsy of the cavitory lesion in 10/08
 - Extensive fibrosis and infiltrate of lymphocytes, plasma cells, and occasional eosinophils, no granulomatous inflammation was seen.
 - No evidence of neoplasia
 - Stains negative for infectious organisms and cultures no growth to date.

Case Presentation: ROS

- Significant constitutional symptoms
 - fever, chills, night sweats, 15-20 pound weight loss in the preceding 2 months, fatigue
- No chest pain, minimal non-productive cough, no hemoptysis
- No arthralgias, some myalgia

Hospital Course

■ ID consult:

- Given the evidence of his cavitary lung lesions, his significant constitutional symptoms with fever, chills, night sweats, and a 10-pound weight loss in the preceding 3 weeks, concern for tuberculosis.
- He was placed on respiratory isolation, was started empirically on anti tuberculous therapy (RIPE regimen)

■ Bronchoscopy with BAL:

- AFB negative

Hospital Course

- Patient clinically improves on Moxifloxacin and Clindamycin
 - Afebrile, no night sweats
 - Stable vital signs
 - Feels more energy
- BAL (+) for *Aspergillus fumigatus*:
 - Day 5, 2/4 tubes

What do you want to do?

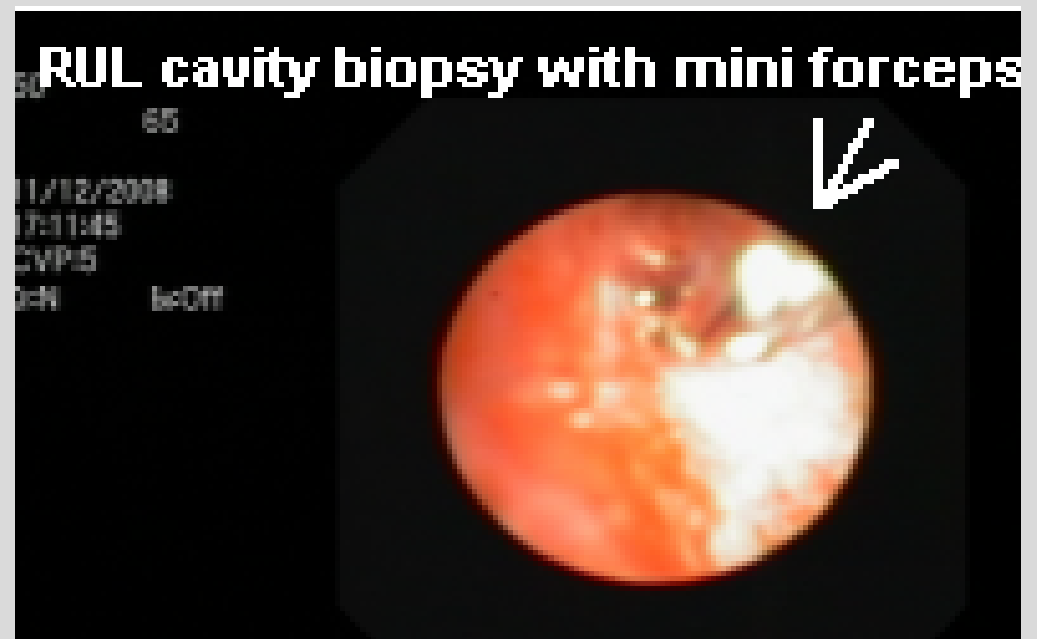
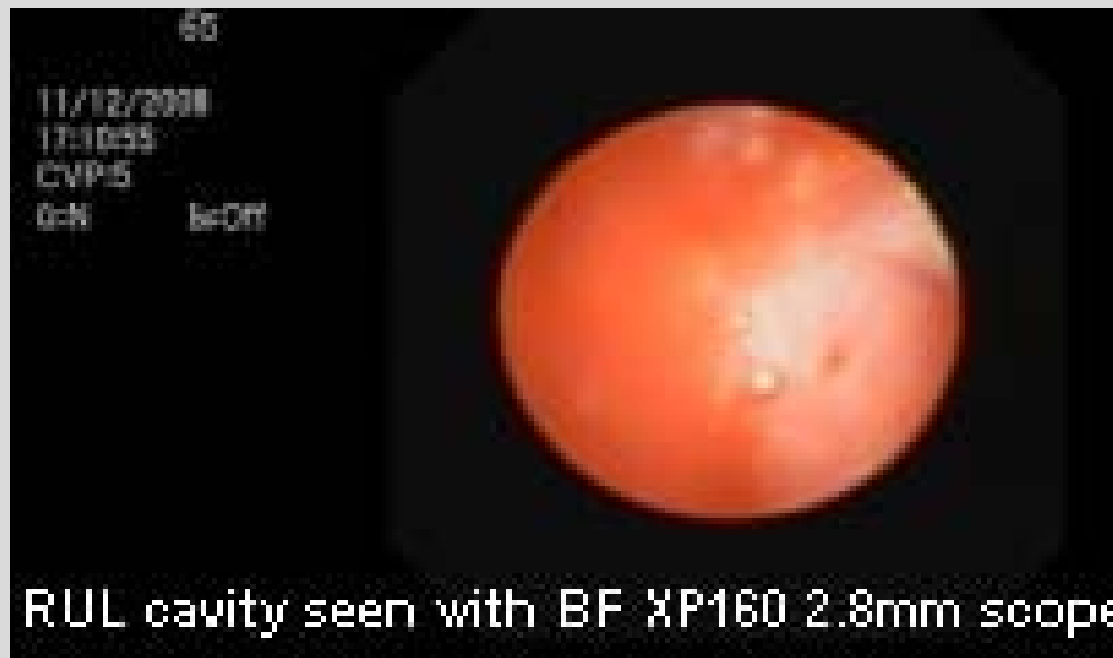1. Ignore culture- it's a colonizing organism
2. Start voriconazole 200 mg oral twice daily
3. Start amphotericin B deoxycholate 1 mg/kg/ day
4. Voriconazole with resection of lung

Hospital Course

- In discussion with ID team
Aspergillus considered a colonizer and not treated
- Working diagnosis: Bacterial necrotizing pneumonia ?
- Discharged with close follow up

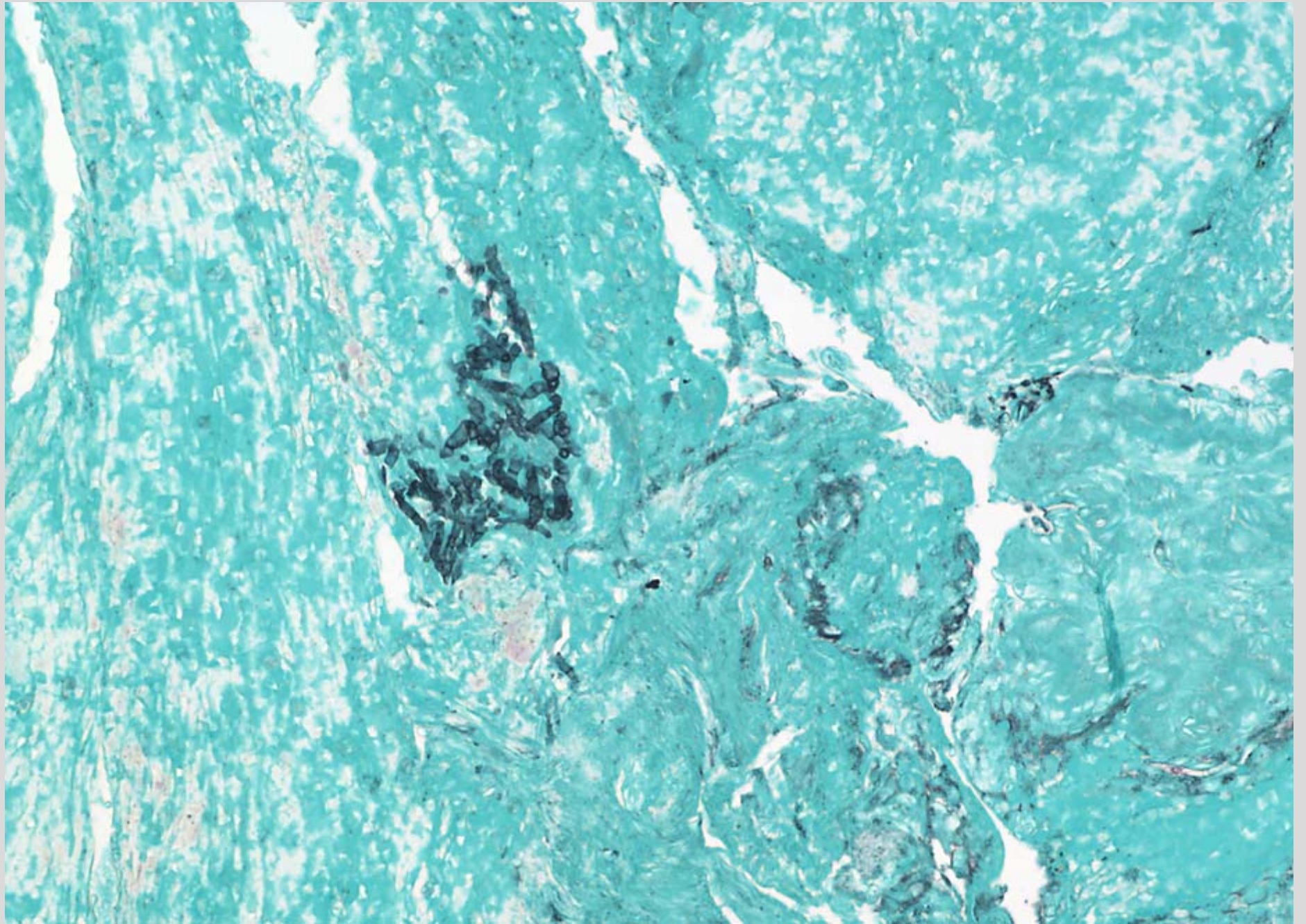
10 days later...

- Patient calls reporting:
 - recurrence of night-sweats and sub-febrile temperature
 - More fatigue
- Prescribed Moxifloxacin and plan for follow up in 2 days
- Interventional radiology



Pathology Report

- Bronchial mucosa and peribronchial soft tissue with necrosis, acute and chronic inflammation, and fibrosis (clinical cavitory lesion). fungal elements, morphologically compatible with aspergillus species. see note. negative for tumor.
- BAL Cytopathology: fungal elements morphologically compatible with aspergillus
- BAL: positive at day 5, 2 of 4 tubes
Aspergillus fumigatus



What is Aspergillosis ?

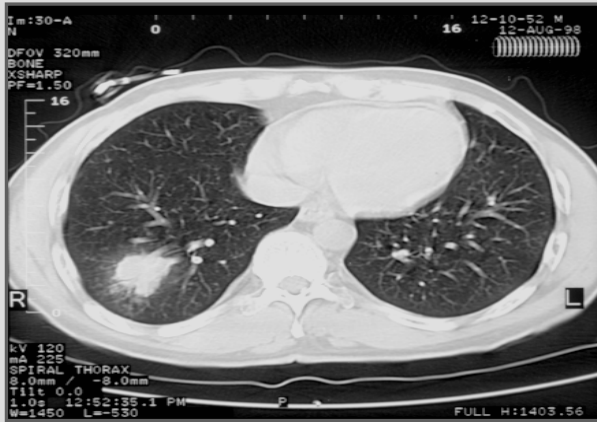- Invasive aspergillosis
 - Acute
- Chronic aspergillosis
 - Chronic, cavitary
 - Chronic, fibrosing
 - Chronic sinusitis
 - Aspergilloma
- Allergic
 - ABPA
 - Extrinsic allergic bronchoalveolitis
 - Asthma with fungal sensitization
 - Allergic sinusitis

Outline

- When to suspect an invasive pulmonary mould infection
- Management
 - Diagnosis
 - Therapy

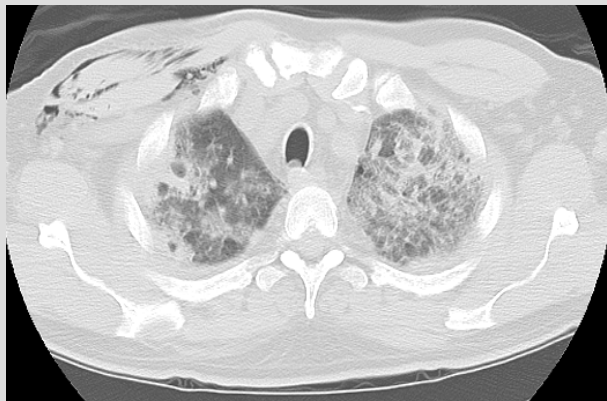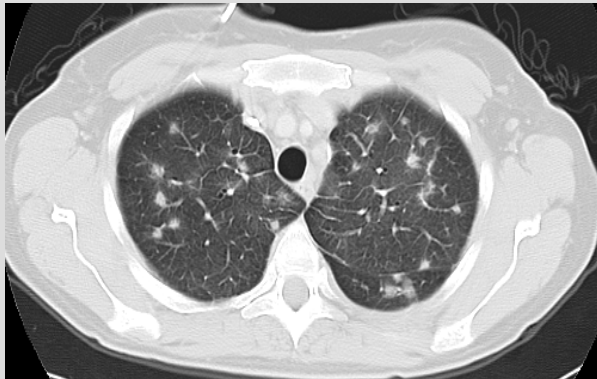When to suspect an invasive pulmonary mould infection

- The right host: risk factors
 - Neutropenia
 - Corticosteroids
 - Other transplant associated immunosuppressants or new antibodies that impact cellular immunity (e.g. infliximab, etc.)
- The right presentation
 - “Typical” radiographic abnormalities



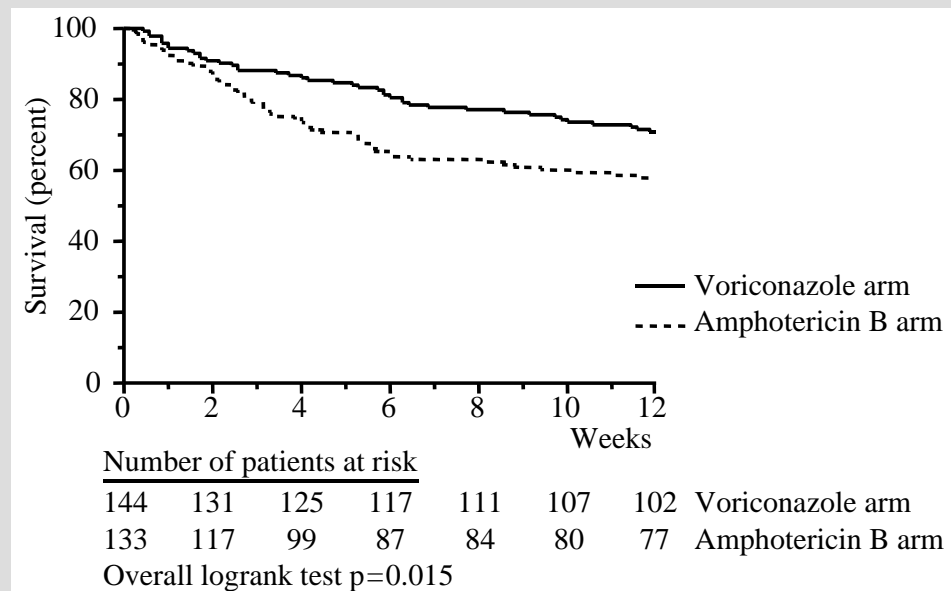
Radiographic Abnormalities Vary

- Nodule +/- halo: typical presentation in neutropenics
- More variability in non-neutropenic patients¹
 - Nodular disease
 - Bronchopneumonia
 - Potentially worse prognosis
 - ◆ Host variable?
 - ◆ Stage of diagnosis?
 - ◆ Difference in disease-Immunopathogenesis?



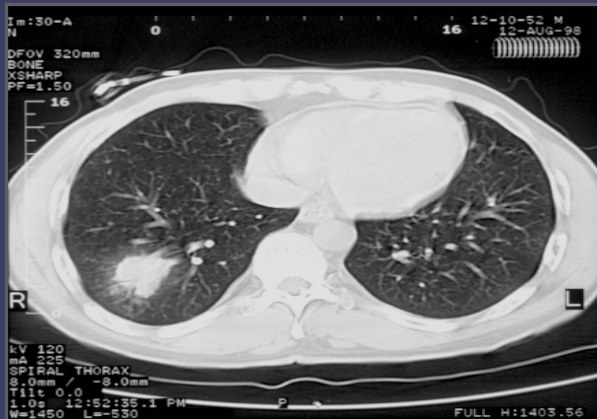Primary therapy of IA

- Voriconazole vs. AmB-d
- Global, randomized, double-blind trial
 - Voriconazole – better responses, better survival



Herbrecht et al, New Eng
J Med 347: 408 (2002)

Question 2



■ 43 yr old M with AML –s/p allogeneic BMT 80 days (GVHD)

– Prednisone 2 mg/kg, CyA

– Cough, fever

■ Therapy:

1. Voriconazole and BAL

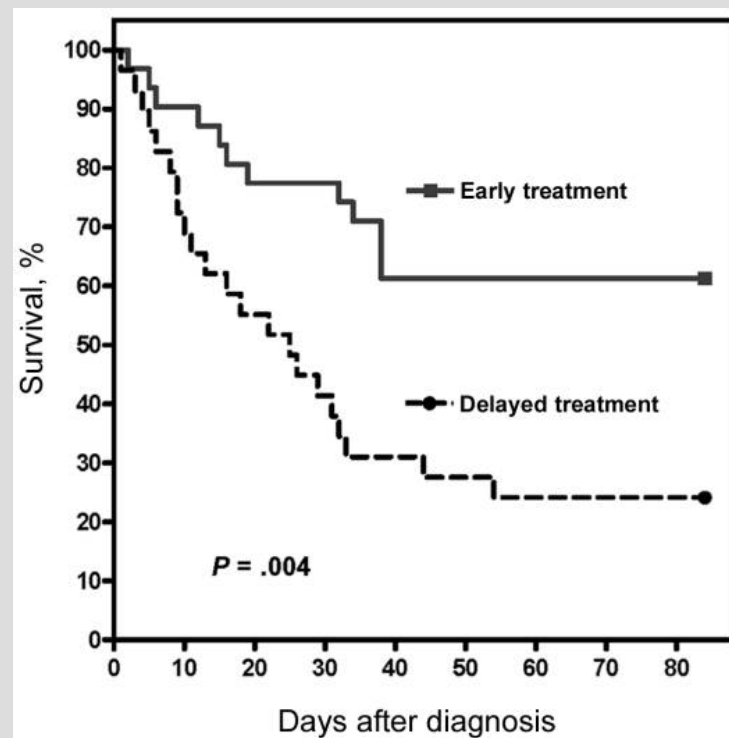
2. Amphotericin and BAL

3. Hold antifungals pending results of BAL

4. Voriconazole and capofungin

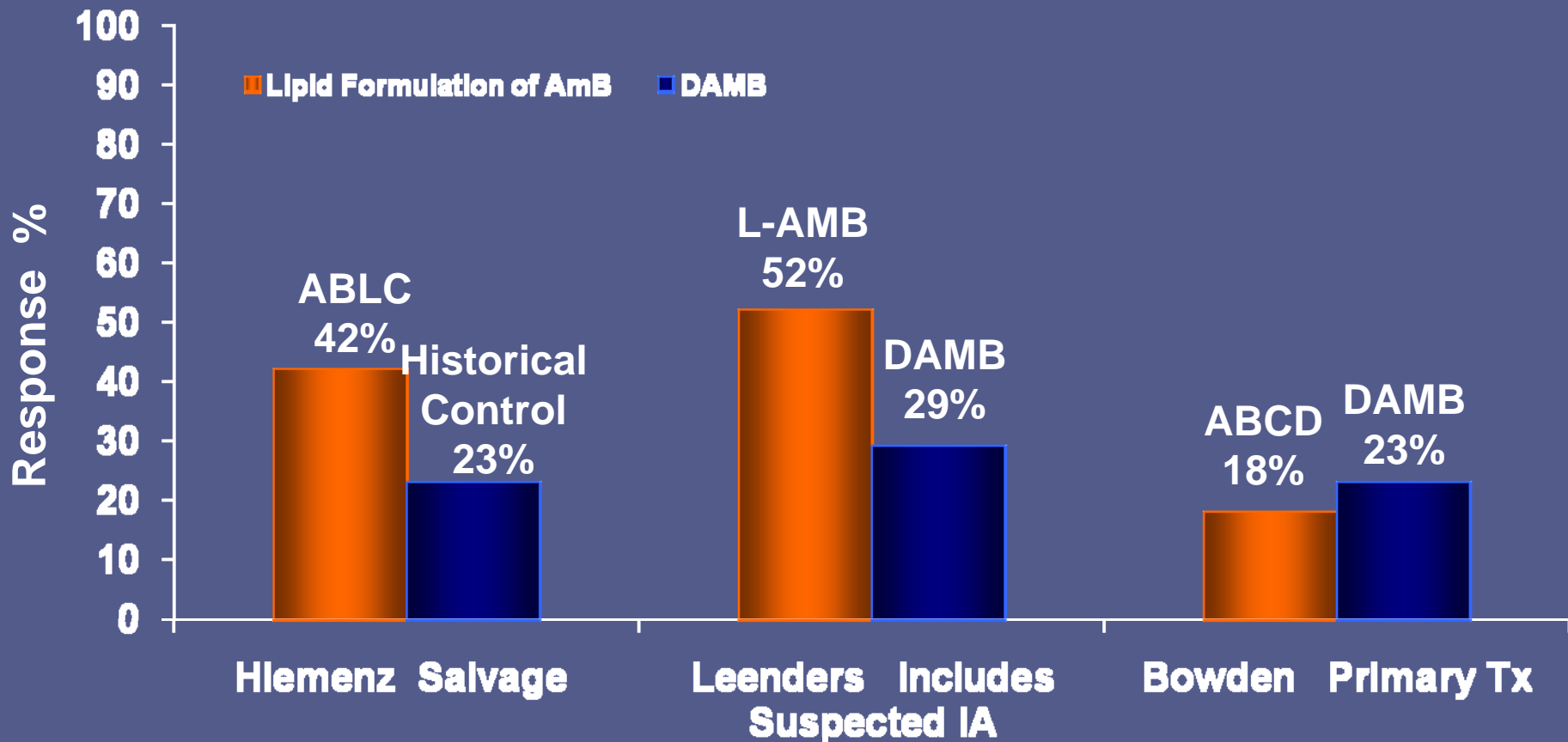
Effect of delayed therapy

- 70 cases of Zygomycetes infection at MD Anderson
- Delayed therapy (> 6 days after diagnosis) associated with worse survival



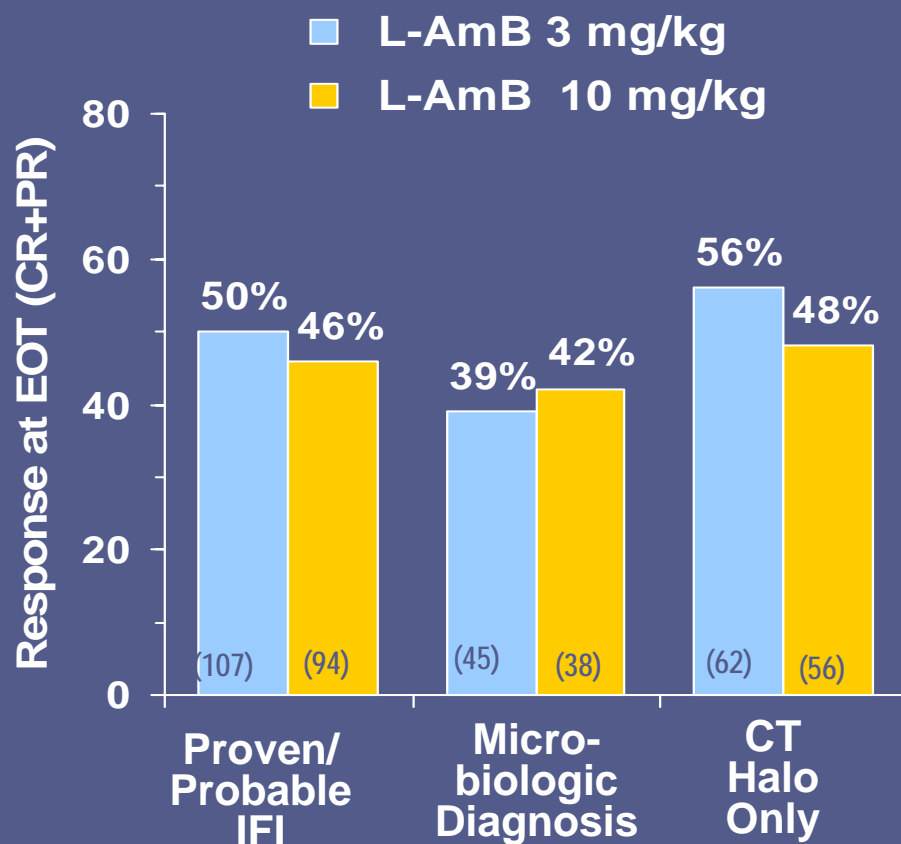
Chamilos et al. Clin Infect Dis 2008; 47:503-9

Polyene Therapy for Invasive Aspergillosis (IA)



Hiemenz JW et al. *Blood* 1995;86(suppl 1):849a; Leenders ACAP et al. *Br J Haem* 1998;103:205; Bowden RA et al. *Clin Infect Dis* 2002;35:359-66.

Efficacy of Liposomal AmB (L-AmB) in Invasive Mycoses: AmBiLoad Trial



14-day loading dose of L-AmB
 3 or 10 mg/kg/d followed by
 L-AmB 3 mg/kg/d

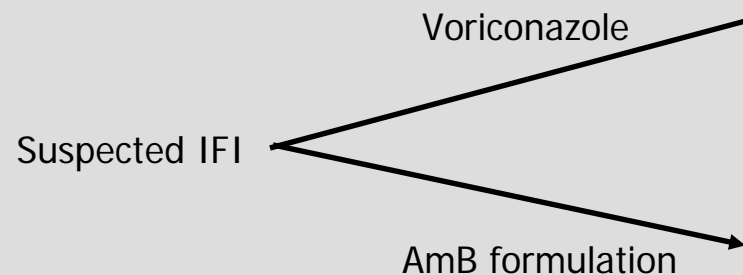
	L-AmB	
	3 mg/kg/d	10 mg/kg/d
IPA	96%	97%
CT Halo	58	60
Allo-SCT	16	19
Neutropenia	71	76
Survival	72	59
Toxicity	20	32

L-AmB = liposomal amphotericin B; CR+PR = complete and partial responses; EOT = End of Therapy;
 IPA = invasive pulmonary aspergillosis; Allo-SCT=allogeneic stem cell transplant
 Cornely O, et al. *Clin Infect Dis*. 2007;44:1289-97.

The Need

Upton et al. Clin Infect Dis
2007; 44(4): 531-40
Nivoix et al. Clin Infect Dis
2008

- Host variables dictate outcome
 - Not simple variables that have been used for categorizing patients (neutropenia, HSCT)
 - Conditioning
 - Type of stem cells
 - Pre-transplant PFTs
- Cannot compare results of different studies
- Need the randomized trial



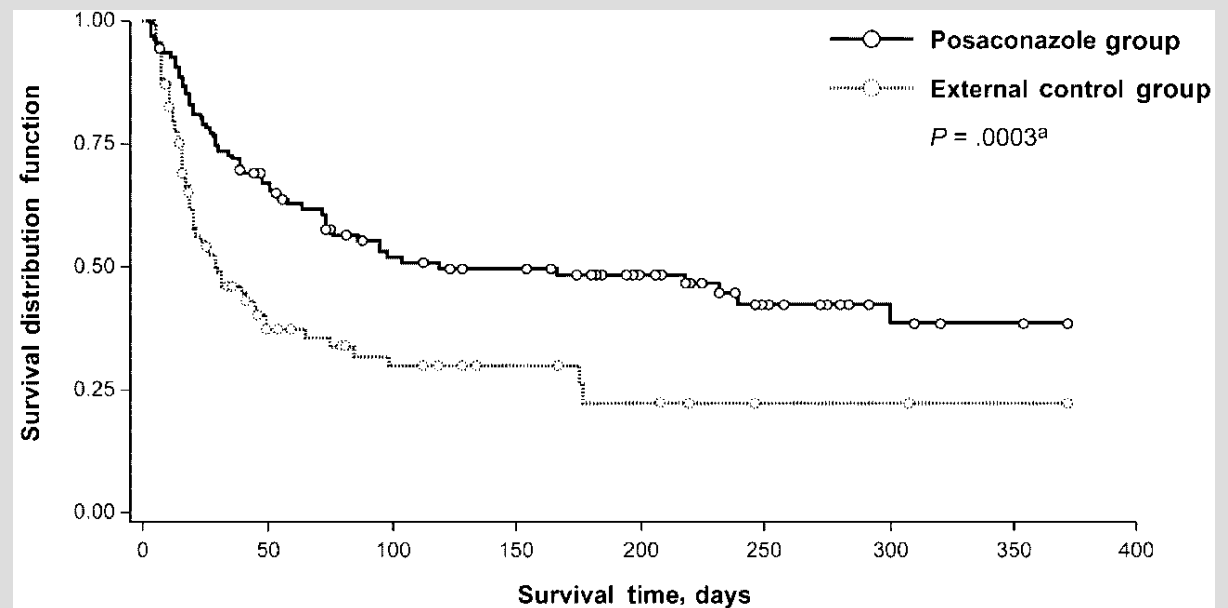
When to start polyene instead

- Abnormalities develop despite long / prior exposure to voriconazole
- Host appears to be at higher risk for zygomycetes infection
 - Vague- late with GVHD, steroid exposure, diabetes, iron overload
- Cannot tolerate azole drugs
 - Particularly common in older people on concomitant calcineurin inhibitors
 - Hallucinations, hepatic abnormalities

Posaconazole

- Posaconazole used as salvage therapy
 - 107 patients, 86 external 'controls'
 - Success rate 42%

Walsh et al. Clin Infect Dis
2007: 44



Echinocandins

- Caspofungin, anidulafungin, micafungin
 - No good randomized trials
 - Caspofungin – salvage therapy study ¹
 - Potentially important immunomodulating activity associated with modulating glucan exposure
 - Echinocandin-treated germ tubes stimulate less secretion of TNF- α , CXCL2 ²
 - Increased glucan exposure increases PMN-induced damage (and dectin-1 expression) ³

¹ Maertens et al. Clin Infect Dis 2004; 39(11): 1563-71

² Hohl et al. J Infect Dis 2008; 198(2): 176085

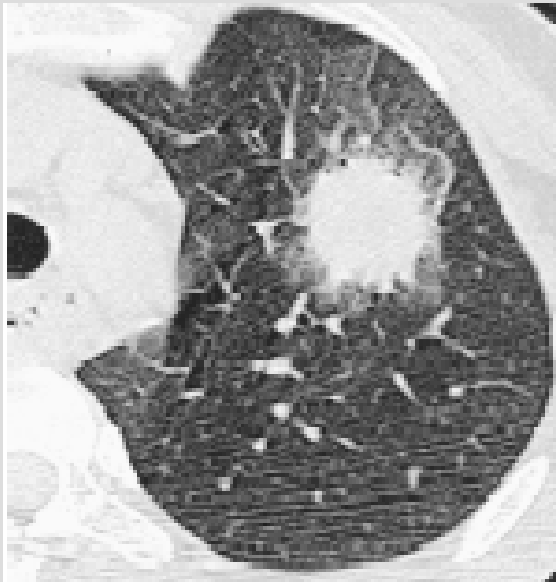³ Lamaris et al. J Infect Dis 2008; 198(2): 186-92

Other therapeutic considerations: What to do if this suspected infection is not responding to your therapy?

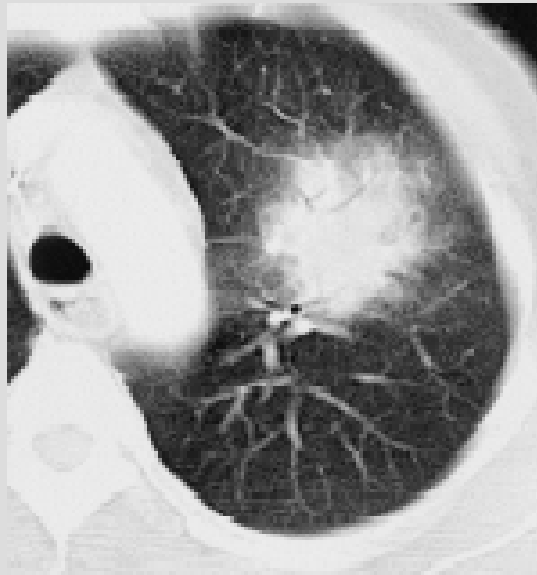- Is this really failure?
- Are you giving enough voriconazole?
- Consider combination therapy?
- Wrong diagnosis – drug?

What defines failure?

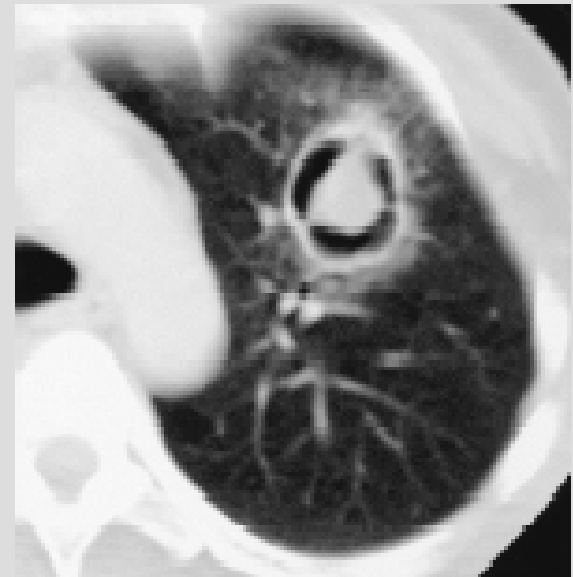
- Not well characterized in the non-neutropenic population
- Be careful about progression of infiltrates early after therapy in neutropenics



Day 0: halo



Day 4: ↑size, ↓halo



Day 7: air crescent

IRIS

- 19 with resolved neutropenia
- Microbiologic improvement (GM) with rad and clinical deterioration

TABLE 2
Definition of Immune Reconstitution Inflammatory Syndrome (IRIS): HIV Patients After HAART vs. Cancer Patients Following Neutrophil Recovery

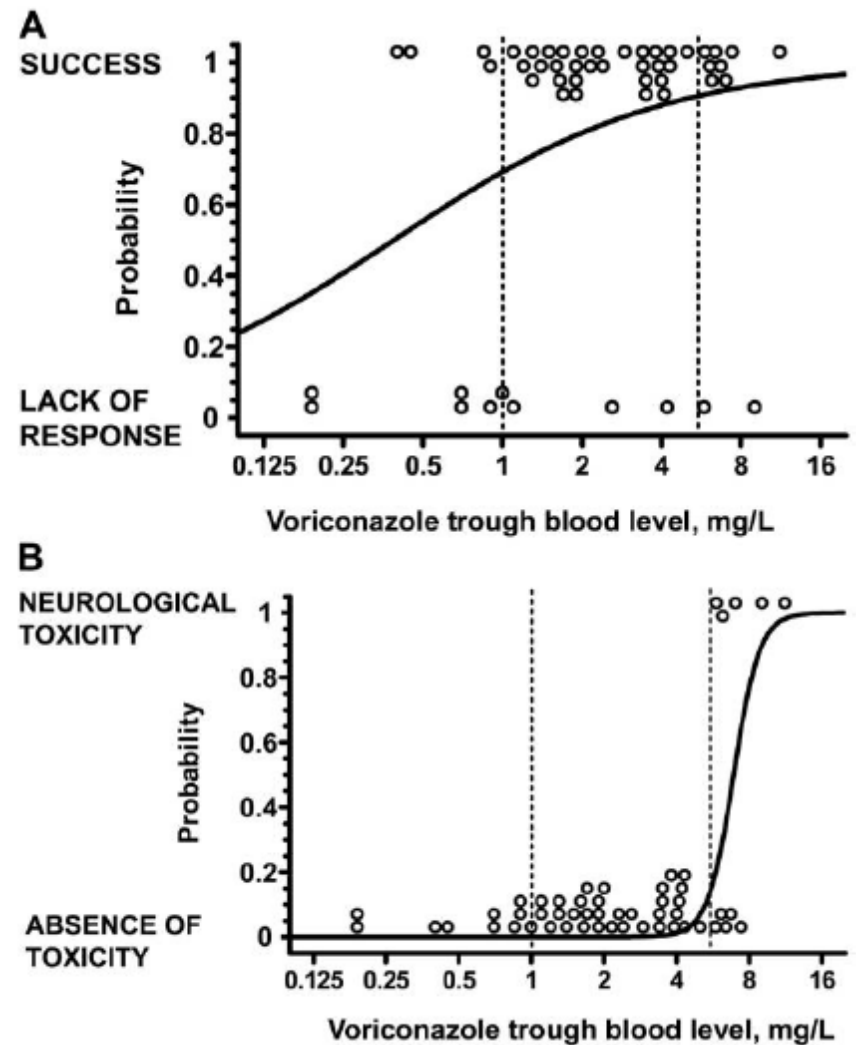
Criteria	IRIS in HIV patients	Pulmonary IRIS in cancer patients with aspergillosis
Required Clinical	Worsening symptoms of inflammation/infection	New onset of or worsening clinical and radiological pulmonary findings consistent with an infectious/inflammatory pulmonary condition
	Temporal relationship with starting antiretroviral treatment	Temporal relationship with neutrophil recovery
	Symptoms not explained by newly acquired infection or disease or the usual course of a previously acquired disease	Absence of new extrapulmonary lesions of aspergillosis (eg, new skin lesions above-described) and after exclusion of other causes, such as newly acquired infection, failure of treatment of a known infection, or medication side effects
Laboratory	$\geq 1 \text{ Log}_{10}$ decrease in plasma HIV load	$\geq 50\%$ decrease in serum GMI titers without treatment modifications
Supportive Clinical		Subsequent resolution of aspergillosis without treatment modifications
	Laboratory	To be determined but likely to include: Immune function studies such as immunophenotype (CD4, CD8, others), cytokines, others
	Biopsy demonstrating well-formed granulomatous inflammation or unusually exuberant inflammatory response	Biopsy demonstrating well-formed granulomatous inflammation or unusually exuberant inflammatory response

IRIS indicates immune reconstitution inflammatory syndrome; GMI, serum galactomannan index.

Voriconazole levels

- Levels can be high or low
- 181 measurements in 2388 days (52 patients)
 - Different clinical conditions
 - Variable levels:
 - Oral- more levels < 1ug/mL (25% of patients)
 - Difficult to measure whether levels corresponded with response
 - Levels corresponded with neurologic toxicities

Pascual et al. CID 2008; 46:201

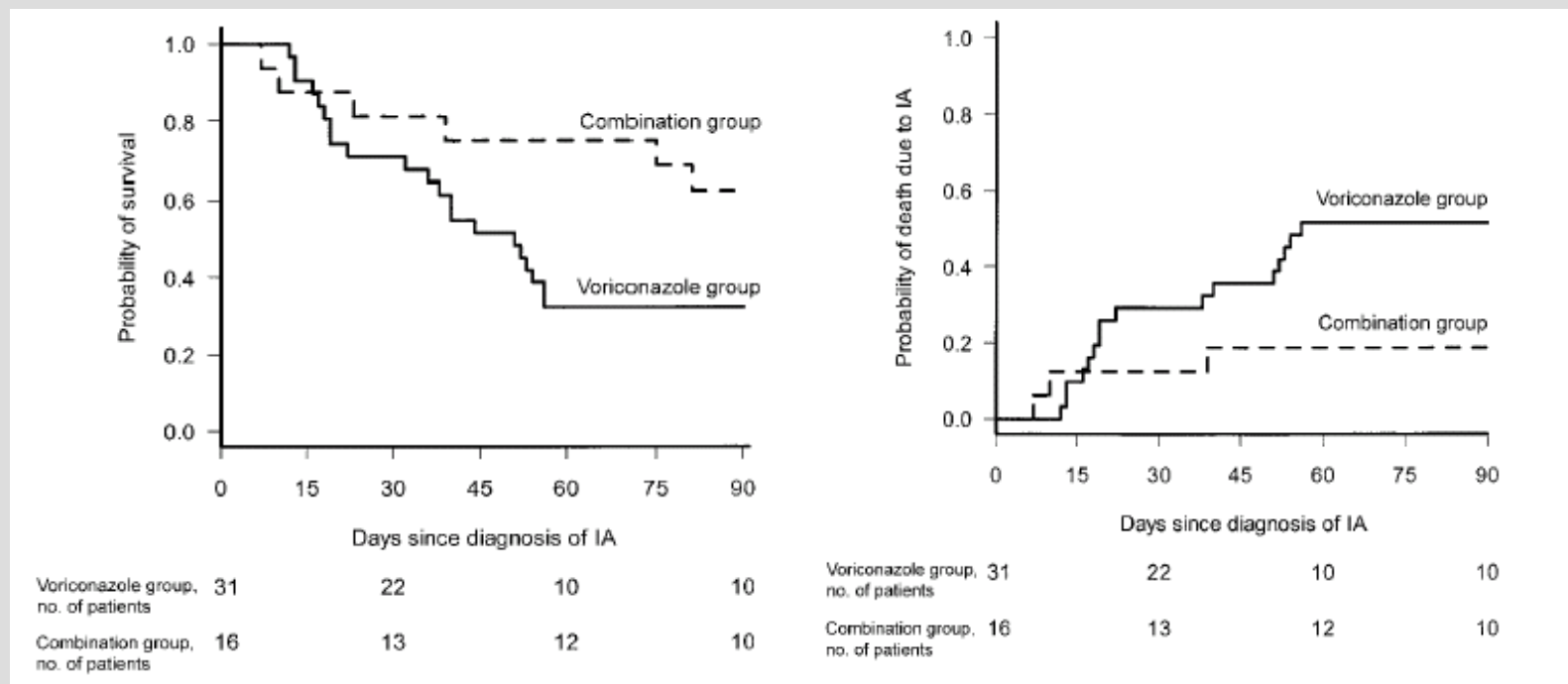


Dosing

- Dose based on weight with oral formulation
- Dose-escalate based on toxicity monitoring (following LFTs)
- Dose-escalate based on therapeutic level monitoring in everyone?
- Higher doses needed in children
 - Start at 6 - 7 mg/kg twice daily

Combination Therapy Vori + CAS

- Salvage aspergillosis. Everyone started on AmB
- Voriconazole vs. Voriconazole + CAS
- Sequential design: 1997-2001



Marr et al, Clin Infect Dis 2004

Variable susceptibility

- Voriconazole 'resistance'
 - Zygomycetes
 - Other case reports
 - *Paecilomyces variotii*
 - *Aspergillus ustus*
 - *Aspergillus fumigatus*
- Beware the slow /non-sporulating organisms identified as *A. fumigatus*^{1,2}
 - *Aspergillus lentulus*¹ (high MICs all antifungals)
 - *Aspergillus udagawae*¹ (high MICs AmB)
 - *Aspergillus alliaceus* (high MICs AmB)
- Azole resistance reported in *A. fumigatus* isolates³
 - 6% of clinical isolates in Netherlands

¹Balajee et al. Euk Cell
2006 5(10): 1705-12)

²Balajee et al. J Clin
Microbiol 2007 45(8): 2701

³ Snelders et al. PLoS Med
2008

Conclusions

- “Aspergillosis” is a spectrum of illnesses
- Suspect invasive mould infections with radiographic abnormalities in hosts at risks
- Diagnosis, to the microbial level, is critically important
 - Differential activities of drugs
- IDSA recommendations for IPA therapy¹:
 - 1^o: Voriconazole
 - 2^o: L-AmB, ABLC, caspofungin, micafungin, posaconazole, itraconazole
- When therapy fails
 - Attention to voriconazole dosing
 - Dose escalation (liver tolerated)
 - Check levels
 - Consider combination therapy
 - Consider alternative diagnosis that would require change in coverage
- Novel treatments being explored

¹Walsh et al. Clin Infect Dis
2008;48: 327-60